

# Close Reduction and Percutaneous Pin Fixation in Displaced (Type-III) Supracondylar Fractures of Humerus in Children Surgical Outcomes and Comparison with other study

MIAN MUHAMMAD AZHAR

## ABSTRACT

**Aim:** To evaluate the results of close reduction and percutaneous pin fixation in displaced supracondylar fractures of humerus (type-III) in children in our population.

**Place and duration of study:** Allama Iqbal Memorial Teaching Hospital/KMS Medical College and National Bone and joint Hospital, Sialkot from June 2008 to December-2013.

**Method:** 65 children, 42 boys and 23 girls with age range between 03 to 11.5 years were treated with Close Reduction and percutaneous pinning of humerus having Type-III Supracondylar fractures of elbow joint. The time duration of trauma and presentation in emergency department range between 04 to 48 hours. The right side was involved in 48 children (73%) and left side in 17 children (26%). Close reduction and percutaneous pin fixation was done in all patients. All patients were discharged in the same day or next day of surgery. The patients were evaluated post operatively radiologically as well as clinically using Flynn's criteria. Usual complications as mentioned in the literature were also studied. Out of 65 patients operated 52 patients (80%) have excellent results, 07 patients (10.75%) good, 02 patients (3.1%) fair and 04 patients (6.2%) have poor results.

**Conclusion:** Closed reduction and percutaneous pin fixation in Gartland Type-III Supracondylar fracture is most effective, reliable, low cost, less time consuming with negligible complication rate and early recovery. It is safe and effective method in managing this type of difficult fractures.

**Keyword:** Type-III Supracondylar fractures, Percutaneous pinning, Flynn's criteria.

---

## INTRODUCTION

Supracondylar Fracture is an extra articular fracture of distal humerus at elbow joint and is most common injury of elbow in children. It accounts 16.6% of all fractures in paediatric patients. About 85% of elbow fractures in children occur in distal humerus and of them 55 to 75% are supracondylar accounting 3.5% of all fractures in children<sup>19,20,25</sup>.

Supracondylar fractures were described first in 3<sup>rd</sup> and 4<sup>th</sup> century in A.D. most of the discussion in 17<sup>th</sup> and 18<sup>th</sup> century were directed towards controversy regarding correct position of immobilization of elbow joint. At the beginning of the 20<sup>th</sup> century more attention was paid towards its outcome and treatment begun to change from conservative to more aggressive and active method.

Clinically these injuries are divided into extension or flexion type as reported by W.Wilkin's<sup>33</sup> in his review series of 4520 cases. He reported that extension types are more common accounting for 90 to 98% of fractures. Later on supracondylar fractures are described by many authors time to time. Presently most common accepted classification is Gartland's classification<sup>12</sup>. Gartland Type-III fractures

are widely displaced fractures. There is no cortical contact between fracture fragment generally medial displacement of distal fragment is more common than lateral displacement. Displaced supracondylar fractures have always presented a challenge in management because of its associated morbidity due to malunion, cubitus varus, loss of elbow function, VIC, compartment syndrome, neurovascular injury leading to lifelong disability<sup>3,4,6,8,22,28</sup>.

Many methods have been proposed including long arm POP cast immobilization, skeletal traction, Dunlop's skin traction<sup>10</sup>, open reduction and K wiring and close reduction and percutaneous pinning. Again there is a wide range of discussion regarding single column fixation, double column fixation, two cross K wire fixation, or one K wire from each side and one additional wire from lateral side in order to achieve stable reduction and good results<sup>1,9,11,13,15,16,18,26</sup>. Close reduction and percutaneous pinning was initially described by Swenson<sup>1</sup> and later on popularize by Flynn's et al<sup>11</sup>.

It is simple procedure which requires less time, no surgical dissection and least post-operative complications. The purpose of the study was to evaluate the results of close reduction and percutaneous pinning in the displaced Type-III supracondylar fracture in our district population.

---

Associate Professor Orthopaedic Surgery, Khawaja Muhammad Safdar Medical College, Sialkot  
Correspondence to Dr. Mian Muhammad Azhar, Associate Professor Email: drzharskt@gmail.com

## MATERIAL AND METHODS

The study was conducted between June 2008 to December-2013 in the department of orthopaedic surgery of Khawaja Muhammad Safdar Medical College and National Hospital, Sialkot. Total 65 patients were included in the study. Initial displacement was classified according to Gartland Classification and only Type-III displaced supracondylar fractures were included in the study. Compound fracture with bone protruding out of wound and ipsilateral supracondylar fractures with fracture distal radius or forearm were also excluded from the study. Inclusion criteria was closed displaced type-III supracondylar fracture of elbow joint.

## RESULTS

Among 65 patients 42(64.61%) were male and 23 (35.38%) were female the age range from 2 years to 12 years the mean average was 4.8 years. The right side was involved in 48(73.84%) and left side in 17 (26.15%) patients. Four patients (6.15%) presented with poor distal pulsation after injury but after reduction it returns to normal and no vascular surgeon opinion was required. All patients were examined post operatively every week upto 4 weeks and then every 2 weeks upto three months and then after every six months using Flynn's Criteria.

We achieve union in all 65 patients (100%) we noted lessening of pin 12 patients, (18.46%) superficial pin tract infection 15 patients, 23%, deep infection 2 patients (3%), decrease in range of movement 17 patients (26%), loss of carrying angle 06 patients (9.2%) myositis ossificans 1 patient, temporary ulnar nerve injury 1 patient (1.5%) and temporary distal vascular impairment in 4 patients (6.45%).

The follow up range from 2 years to 5.6 years with an average follow up of 3.2 years. During follow up every patient was examined radiologically and clinically using Flynn's criteria, functional and aesthetic assessment was done and our study shows that 52 patients (80%), have excellent, 7 patients (10.75%) good, 2 patients (3.7%) fair and four patients (6.15%) poor results. Overall satisfactory results were (93.15%) and unsatisfactory results were (6.15%). We also compare our results with the results of the other studies mentioned in the literatures. Our operating procedure was different in two ways then mentioned in other studies.

1. We use short hypnotic like Propofol or Ketamine (IV Anaesthesia) (although we have everything ready for general anaesthesia in case if require) and procedure is finished in 15 to 20 minutes.

2. We use lateral or semi prone position for surgery. The surgeon stands to the opposite side of the fracture limb and assistant on fracture side. The patient arm is pronated and flexed. We achieve reduction by applying traction in upward direction and then by thumb pressing the olecranon. The assistant keep the counter traction in the opposite direction. At the same time Mediolateral displacement is also corrected. Now reduction is also checked in lateral view, (note) we do not rotate the elbow joint to check lateral view but our C-arm technician move the C-arm in lateral direction hence thereby reducing the chance of loss of reduction by this maneuver.

Age distribution of patients

Age (Years)	n	%age
2 to 4 years	32	49.23
5 to 10 years	25	38.46
10 to 12 years	8	12.30

Assessment according to Flynn's Criteria

Outcome	Cosmetic factors loose of carrying angle degree			Functional factors loose of ROM (degree)	
	Range degree	n	%age	n	%age
Excellent	0 to 5	2	1.9	7	10.76
Good	6 to 10	3	4.6	9	13.84
Fair	11 to 15	1	1.5	3	4.61
Poor	>15	0	0	2	3.07

Overall results according to Flynn's Criteria

Excellent	52	80
Good	7	10.76
Fair	2	3.07
Poor	4	6.15

Complications

Name	n	%age	Name	n	%age
Lose of Range of Movement	17	26.5	Myositis Ossificans	0	0
Lose of Carrying angle	6	6.7	Compartment Syndrome/VIC	0	0
Loosening of Pin	12	18.46	Radial Nerve Injury	0	0
Superficial Pin Tract Infection	15	23	Temporary Ulnar Nerve Injury	1	1.5
Deep pin tract Infection	2	3	Temporary Poor Distal Vascular Perfusion	2	4.6

Now after obtaining the stable reduction and its confirmation on both views we pass cross K wires from medial and lateral column penetrating the opposite cortex. While passing K wire from the medial side we reduce the elbow flexion from 120 degree to 80 to 90 degree in order to prevent iatrogenic ulnar nerve injury. In some cases we also passes an additional K wire from lateral column in case of sever comminution when additional stability is required. Now after obtaining stable reduction and

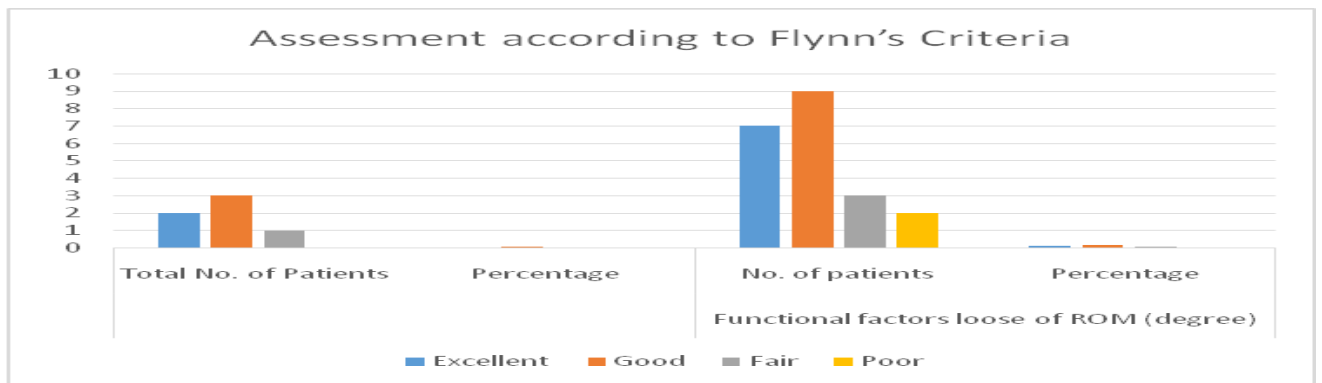
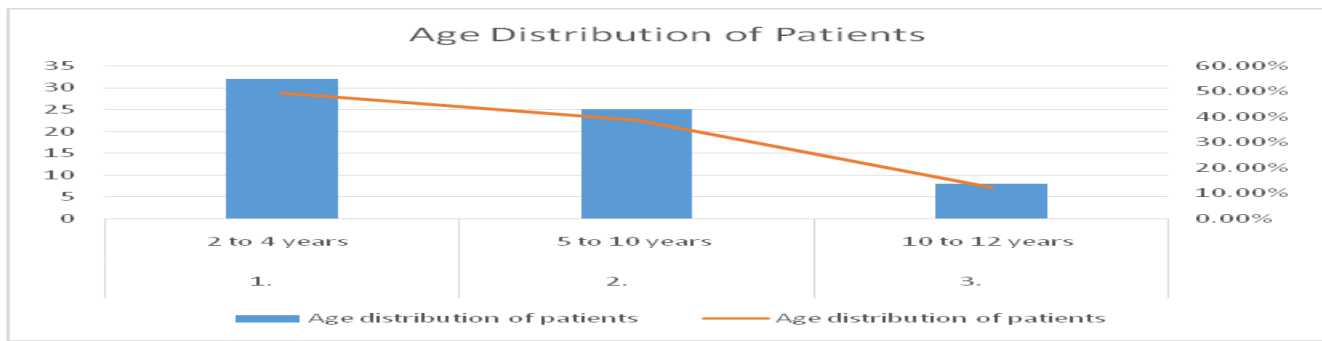
fixation we pad the pin tract and apply POP back slab to already flexed and pronated forearm. We gave one dose of post operative antibiotic IV followed by 5 day's course of antibiotic suspensions alongwith pain killer syrup.

Post Operative X-rays were taken on the same day before discharging the patient then after one

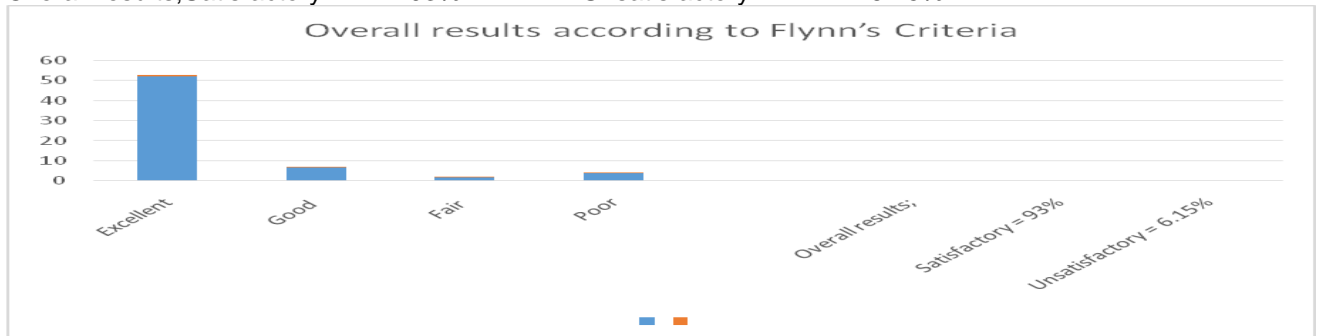
week and third week of surgery. POP black slab and K-wire removed after 03 to 04 weeks following fracture union and patients and parents are instructed to have range of motion exercises. Again during follow up every patient was assessed using Flynn's Criteria.

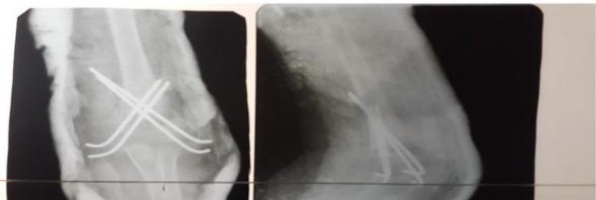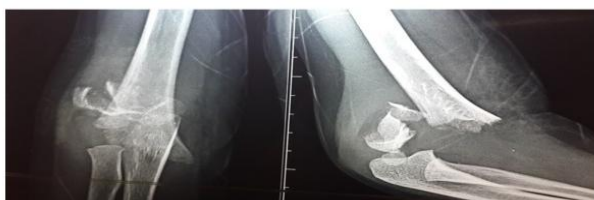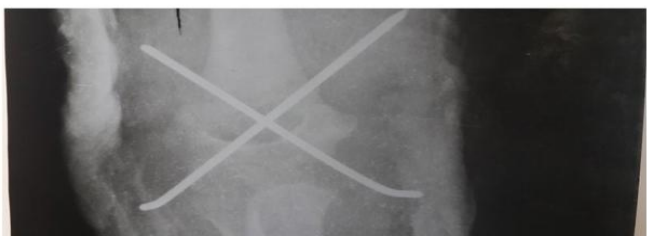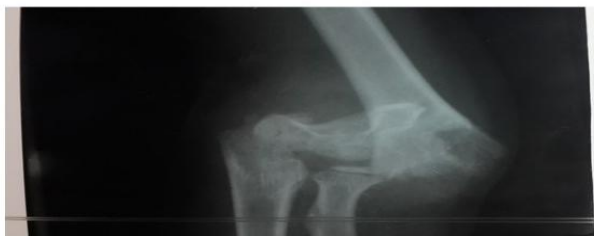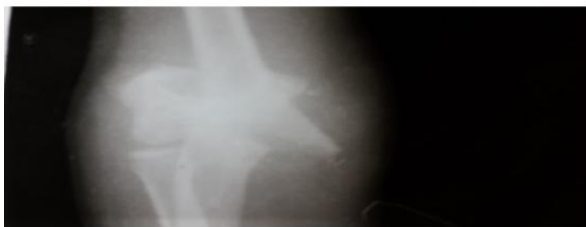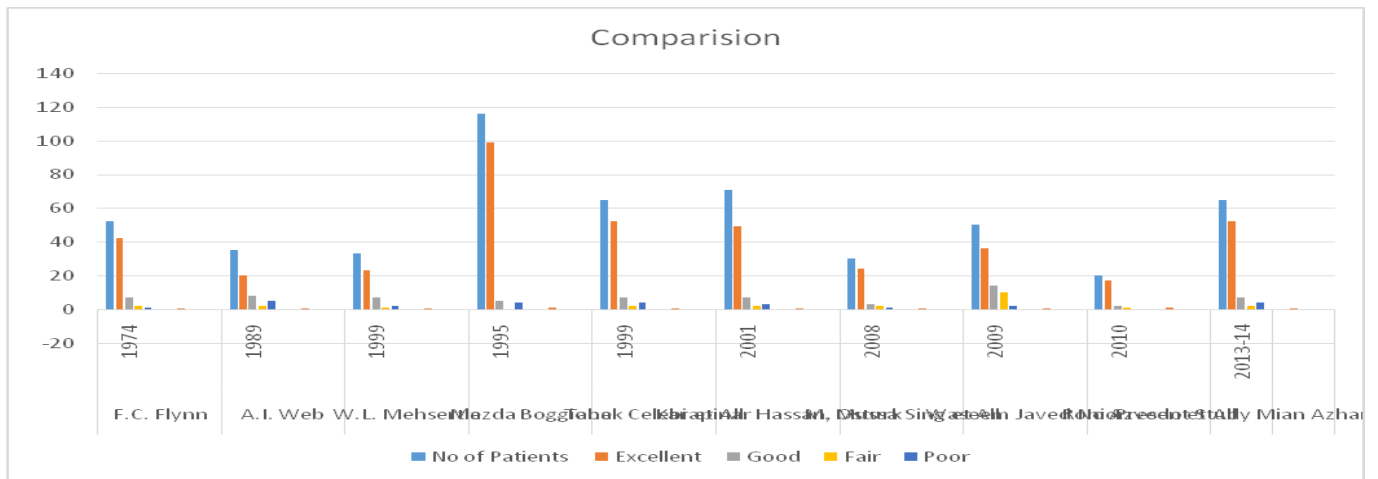
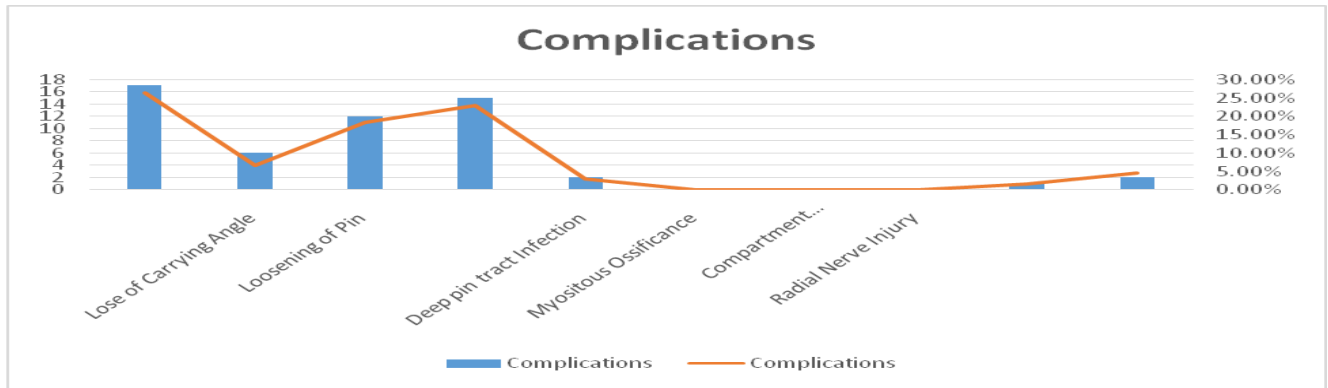
Table showing Comparison with other studies

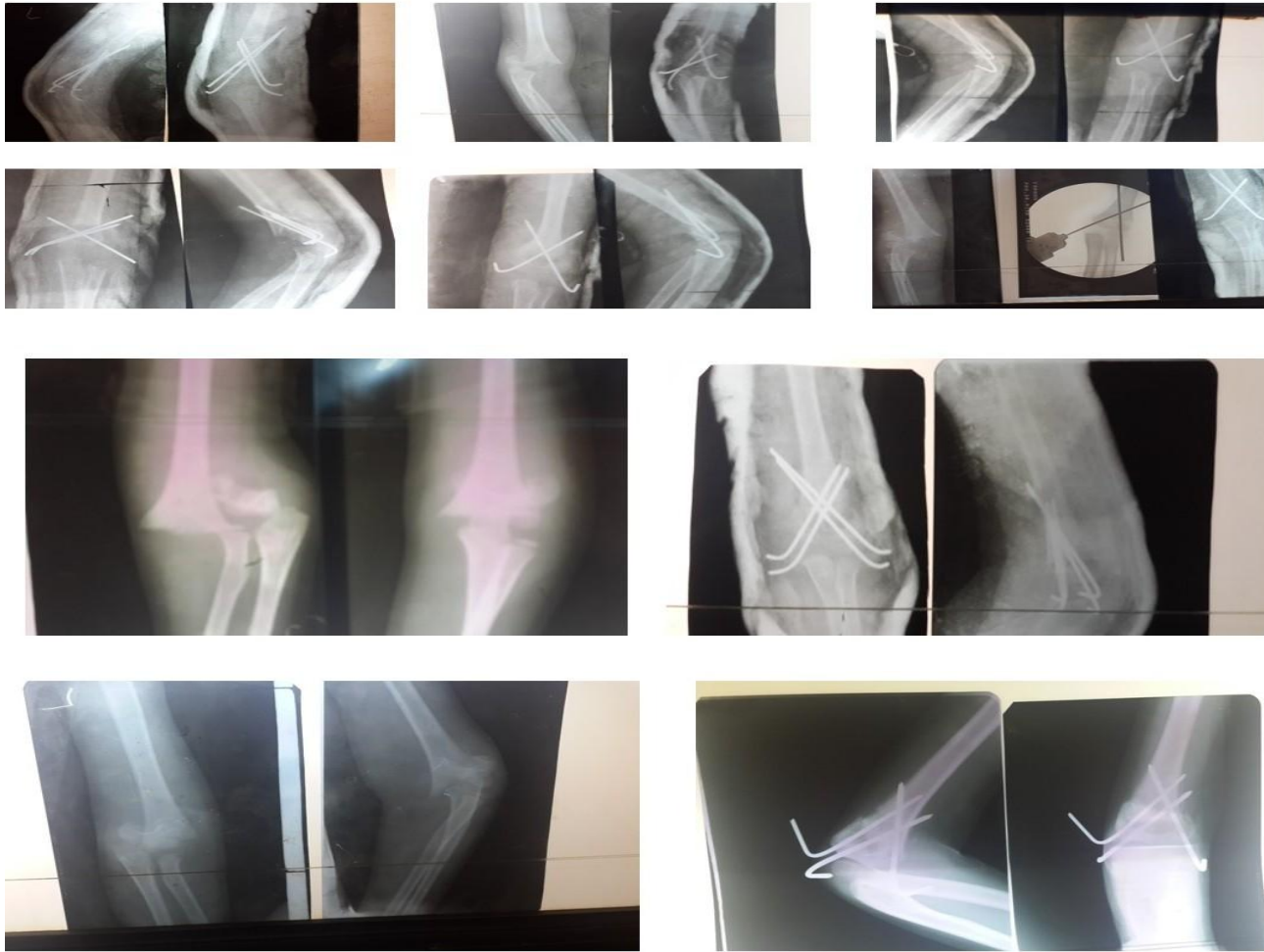	F.C. Flynn	A.I. Web	W.L. Mehserle	Mazda Boggione	Tabak Celebi et al	Karapinar Hassan, Osturk	M. Mussa Sing	Waseem Javed Noor	Roni Azvedo et al	Present Study
Year	1974	1989	1999	1995	1999	2001	2008	2009	2010	2013-14
No of pts.	52	35	33	116	65	71	30	50	20	65
Excellent	42(81%)	20 (57%)	23 (70%)	99 (91.6%)	52(80%)	49 (80.3%)	24(80%)	36 (72%)	17(85%)	52 (80%)
Good	07(13%)	08(23%)	07 (21%)	05 (4.6%)	07(6.76%)	07 (11.5%)	03(10%)	14 (28%)	02(10%)	07(10.76%)
Fair	02(0.4%)	02 (6%)	01 (0.4%)	0 (0%)	2(3.07%)	2 (3.3%)	2(6.7%)	10 (20%)	1 (5 %)	2 (3.07%)
Poor	01(0.2%)	05(14%)	02 (6%)	04 (3.7%)	04(6.15%)	03 (5%)	01(0.3%)	02 (4%)	0 (0%)	4 (6.15%)



Overall results; Satisfactory = 93%      Unsatisfactory = 6.15%







## DISCUSSION

As we know supracondylar fracture of elbow is most common fractures in children which presents in first decade of life. The management of displaced fractures is more challenging for orthopaedic surgeons. Various methods have been reported in literature for the treatment of Supracondylar fractures of elbow joint. There are various studies which have shown the advantages and disadvantages of different operative techniques. The aim of all operative treatment to restore the normal anatomical reduction and functional outcome of patient in order to prevent lifelong disability. Although good results have been reported by close reduction POP cast, Dunlupe traction, overhead skeletal traction, open reduction and internal fixation, but literature is also full of reported complications in which cosmetic deformity of cubitusvarus and loss of range of movement are most important and require attention<sup>1,2,10,11,12,19,27</sup>.

The disadvantages of close reduction are loss of reduction due to repeated manipulation, elbow stiffness, loss of range of movement, myositis ossificans and unnoticed compartment syndrome

that can lead to dangerous outcome. The disadvantages of skeletal traction includes elbow stiffness, pin tract infection, prolonged hospital stay and high incidence of recurvatum deformity of elbow joint. Operative reduction although allows exact reduction under vision but it involves lot of soft tissue dissection, extensive surgery and may lead to neurovascular injury, myositis ossificans and elbow stiffness leading to bad results<sup>5,6,7,12,17,31,33</sup>.

Displaced supracondylar fractures of elbow joints managed by close reduction and percutaneous pinning have demonstrated encouraging results with respect to union, cosmetic and functional improvement since it has been introduced. Swenson in 1948<sup>36</sup> was first to introduce this method but it is later popularized by Flynn's, Wilkins, Aronsen DD, Prager, Brown and Zinar, Campbell's and Waters. In literatures different researchers have recommended single column and double column fixation with cross K wire from each column or three pin fixation from lateral column or one from medial and two from lateral column each advocating advantages and

disadvantages of these techniques<sup>5,6,8,11,13,14,15,16,17,18,23,26,36</sup>

Olcay's et al compared the fixation technique used in displaced supracondylar fractures of humerus anatomically and biomechanically by using torsional strength in an adult cadaver model and reported that the most severe against rotational strength was achieved by fixing a third K wire from lateral side in addition to two cross K wire from each column and he reported that two cross K wire give less resistance as compared to three K wire fixation technique. Herzenberg et al<sup>21</sup> in their study of dog models reported that two cross K wires from medial and lateral column gives best fixation while Earip et al reported in his series of 35 patients that three K wire techniques provides good stabilities and results as well. The different K wire techniques were adopted to get stable fixation on one hand while on the other hand to avoid iatrogenic ulnar nerve injury. Several methods have been used to decrease the risk of ulnar nerve injury, Arino, Luch, Fowler, Kassab, Skaggs, Cluck, Shanon, Mohan, Chacko, have reported their own experience Wind et al suggested to stimulate the ulnar nerve either by small needle or by K wire itself before surgery to see the response of ulnar nerve. Lee et al<sup>27</sup> reported that if we placed divergent k wires from lateral side it give enough stability to fracture site hence there is no need to put K wire from medial side thereby eliminated the risk of damaged to ulnar nerve. Brauer et al<sup>6</sup> and Woratanarat et al<sup>41</sup> stated that chance of ulnar nerve are 2 to 4 times more if we passed two cross K wires hence recommended two parallel lateral K wire fixation only. Levent Karapınor<sup>25</sup> Hassan, Ozturk et al have reported that while passing K wire from lateral side if we decrease the elbow fraction the clinical incident of iatrogenic ulnar nerve injury is reduced. Although this decrease was important clinically but by statistical analysis Fisher's accuracy test ( $p > 0.05$ ) it is not found significant. The same department reported iatrogenic ulnar injury in 27 of 258 patients (11.8%) who under went the same procedure. Although according to Flynn's criteria the clinically results were 95% satisfactory in both studies including 258 and 60 patients and there was no significant difference between them (P.0.05)<sup>3,9,11,13,15,16,18,24</sup>.

In our study in the majority of the case we have done two K wire fixation. In 13 cases 20% we have used two K wires from lateral side and one from medial side but we did this only in cases where we found severe comminution in fracture fragments in order to get stable fixation. We also believe that this method is safe and provide good results not with relation to stability of fracture side but if ulnar nerve injury is present after wiring we can safely remove

the K wire from the medial side as chance of mal-union and loss of reduction is less.

Cubitusvarus is considered to be most common late complication in this type of fractures. Ronie Azwedo, Nelson Franco et al reported 20% incident in their series of 20 children where as the other author has also reported low rate of around 10% in their study. The initial deviation and ligamentotaxis are main factors mechanically influencing the final results of fractures. The lateral ligaments are stronger in pronation and relaxed in supination. Despite anatomical reduction rotation deformity of distal fragment may occur when the wires are not positioned in the same plan especially when one wire is located anterior to other. Ronie et al reported satisfactory results according to Flynn's Criteria inspite of high incidents 20% of cubitusvarus deformity in their series. In our series we have two patients (3.07%) who have cubitusvarus deformity and were rated in poor grade<sup>30,31,34</sup>.

Skagges D L et al and Omid. Chooi in 2008 have reported the incident of vascular injury 20% in displaced supracondylar fractures. Upto 1/3<sup>rd</sup> of the patients present with decrease or absent radial pulse but usually because of good collateral circulation the hand appears to have good perfusion, in such patients no emergency vascular surgical intervention is required but if there is any concern about perfusion of distal extremity the fracture must be reduced even before any vascular study. This is also recommended by AAOS Guidelines. However if perfusion is inadequate after reduction the consultation with vascular consultant for exploration of anti cubital fossa is required. In our study four patients presented with poor vascular perfusion but we did emergency fracture reduction and achieved satisfactory perfusion. None of our patients required vascular surgery<sup>8,22,29</sup>.

Most of the studies have shown that incidents of compartment syndrome is low in isolated supracondylar fractures of humerus but if child is having ipsilateral supracondylar elbow fractures along with fractures of forearm or distal radius, the incidence increases upto 33% as reported by Blackemore et al in his study. In our series none of our patients developed compartment syndrome<sup>3,6</sup>.

So we reached to the conclusion that close reduction and percutaneous pin fixation is safe, reliable, effective, low cost, less time consuming with better recovery and negligible complications and is a procedure of choice and should be preferred to other protocols of treatment in Type-III supracondylar fractures of elbow joint.

## REFERENCES

1. Arino VC, Lluch EE, Ramirez AM et al Percutaneous fixation of supracondylar fractures of the humerus in children. *J Bone Joint Surg Am* 1997 59:914,
2. Aronson D.D., Prager B.I. Supracondylar fractures of the humerus in children. A modified technique for closed pinning. *ClinOrthopRelat Res.* 1987;219:174–184.
3. Aronson DD, Prager PI Supracondylar fractures of the humerus in children: a modified technique for closed pinning. *ClinOrthopRelat Res* 1987 219:174–184,
4. Aronson DD, Prager BI. Supracondylar fractures of the humerus in children a modified technique for closed pinning. *Clinorthop* 1987;219:174-84.
5. Boyd DW, Aronson DD. Supracondylar fractures of the humerus a prospective study of percutaneous pinning. *J pediatrorthop* 1992;12:789-94.
6. Brauer CA, Lee BM, Bae DS, Waters PM, Kocher MS. A systematic review of medial and lateral entry pinning versus lateral entry pinning for supracondylar fractures of the humerus. *J pediatrorthop.* 2007;
7. Canale ST. Fraturas e luxações em crianças. *Rev Bras Ortop* 2006;41(1):10a. Sao paulo manole;
8. Celiker O, Pestilci FI, Tuzuner M Supracondylar fractures of the humerus in children: analysis of the results in 142 patients. *J Orthop Trauma* 1990, 4:265-6. Eid AM Reduction of displaced supracondylar fractures of the humerus in children by manipulation in flexion. *ActaOrthopScand* 1978 49:391.
9. Cheng JC, Shen WY. Limb fracture pattern in different pediatric age groups: a study of 3,350 children. *J orthop trauma.* 1993;
10. D' Ambrosia RD. Supracondylar fractures of humerus—prevention of cubitus varus. *J Bone Joint Surg Am.* 1972;
11. D'Ambrosia R.D. Supracondylar fractures of humerus – prevention of cubitus varus. *J Bone Jt Surg Am.* 1972;54:60–66.
12. Damsin JP, Langlais J. supracondylar fractures. *Rev chirorthopReparatriceAppar Mot* 1987;73:421-36.
13. Dunlop J. Transcondylar fracture of the humerus in children. *J Bone Jt Surg Am.* 1939;21:59–73.
14. Flynn J.C., Matthews J.G., Benoit R.L. Blind pinning of displaced supracondylar fracture of the humerus in children. Sixteen years' experience with long-term follow-up. *J Bone Jt Surg Am.* 1974;56:263–272.
15. Flynn JC, Mathews JG, Benoit RL Blind pinning of displaced supracondylar fractures of the humerus in children. *J Bone Joint Surg Am* 1974 56:263–273.
16. Flynn JC, Matthews JG, Benoit RL. Blind pinning of displaced supracondylar fractures of the humerus in children, Sixteen years experience with long-term follow-up. *J Bone Joint Surg Am* 1974;
17. Flynn JC, Matthews JG, Benoit RL. Blind pinning of displaced supracondylar fractures of the humerus in children sixteen year experience with long-term follow-up. *J Bone Joint Surg (AM)* 1974;56:263-72.
18. Fumo C, Bongiovanni RR, Dobashi ET, Pascarella L, Righi LCS. Fraturas supracondilíneas de umero na infância. *Arq Bras Clin Saude* 2009;35;
19. Hanlon CR, Estes WL Fractures in children: a statistical analysis. *J Bone Joint Surg Am* 1954 87:312.
20. Hart GM, Wilson DW, Arden GP The operative management of the difficult supracondylar fracture of the humerus in the child. *Injury Br J Accid Surg* 1977,
21. Herzenberg JE, Koreska J, Carroll NC, Rong M. biomechanical testing of pin fixation techniques for pediatric supracondylar elbow fractures. *Orthop Trans* 1988;12:678-9.
22. Herzenberg Jt, Koreska J., Carroll N.C., Rang M. Biochemical testing of fixation technique for pediatric supracondylar elbow fractures. *Orthop Trans.* 1988;12:678–679.
23. Hungria MM, Zoppifilho A, Montenegro NB. Fraturas supracondilíneas do umero em crianças: estudo de 90 casos. *Rev Bras Ortop* 1997;
24. Hungria Neto JS, Fregoneze M, Bezerra MJC, Teixeira AA, Yoneda T Fraturas supracondilíneas do umero na infância: avaliação do resultado do tratamento cirúrgico. *Rev Bras Ortop* 1996;
25. Karapinar L, Surenkok F, Ozturk H, Us MR. Çocuk humerus deplase tip 3 suprakondiler kırıklarda erken kapalı reduksi-yon+percutan cerrahi. *Artroplastik Cerrahi* 2003;14:164-75.
26. Lal GM, Bhan S. Delayed open reduction for supracondylar fracture of the humerus. *Int orthop.* 1991;
27. Lee SS, Mahar AT, Miesen D, Newton PO. Displaced pediatric supracondylar humerus fractures. Biomechanical analysis of percutaneous pinning techniques. *J Pediatr Orthop* 2002;22:440-3.
28. Lyons JP, Ashley E, Hoffer MM. ulnar nerve palsies after percutaneous cross-pinning of supracondylar fractures in children elbows. *J pediatrorthop* 1998;18:43-5.
29. Mostafavi HR, Spero C. crossed pin fixation of displaced supracondylar humerus fractures in children. *Clin Orthop Relat Res* 2000;(376):56-61.
30. Pirone AM, Graham HK, Krajcovich JI Management of displaced extension type supracondylar fractures of the humerus in children. *J Bone Joint Surg Am* 1988 70:641–650.
31. Pirone AM, Graham HK, Krajcovich JI. Management of displaced extension-type supracondylar fractures of the humerus in children. *J Bone Joint Surg Am.* 1964;46;
32. Rasool MN. Ulnar nerve injury after K-Wire fixation of supracondylar humerus fractures in children. *J pediatrorthop* 1998;18:686-90.
33. Results of treatment of displaced supracondylar humeral fractures in children by percutaneous lateral cross-wiring technique. *Strategies Trauma Limb Reconstr.* 2008 Apr;3(1):1-7.
34. Supracondylar fractures of the humerus in children. *J Pediatr Orthop.* 1989 9(3):315-25,
35. Supracondylar fractures of the humerus: a prospective study of percutaneous pinning. *J Pediatr Orthop.* 1992 12(6):789-94.
36. Swenson A.L. The treatment of supracondylar fractures of the humerus by Kirschner-wire transfixion. *J Bone Jt Surg Am.* 1948;30:993–997.
37. Treatment of the displaced supracondylar fracture of the humerus (type III) with closed reduction and percutaneous cross-pin fixation. *J Pediatr Orthop.* 1991 11(6):705-11.
38. Turk CY, Baktir A, Argun M, Sahin V, Karakes ES. Displaced supracondylar fractures of the humerus (type 3) in children: A prospective study of percutaneous pin fixation. *Artroplastik Cerrahi* 1997;8:37-40
39. Warlock P. Supracondylar fractures of the humerus. Assessment of cubitus varus by the baumann angle. *J Bone Joint Surg Br.* 1986;68
40. Wilkins KE The operative management of supracondylar fractures. *Orthop Clin North Am* 1990 21:269,
41. Woratanarat P, Angsanuntsukh C, Rattanasiri S, Attia J, Woratanarat T, Thakkinstian A, Meta-analysis of pinning in supracondylar fracture of the humerus in children, *J orthop Trauma* 2012;
42. Zionis LE, McKellop HA, Hathaway R. torsional strength of pin configurations used to fix supracondylar fractures of the humerus in children. *J Bone Joint Surg (AM)* 1994;76:253-6
43. Zionis L.E., McKellop H.A., Hathaway R. Torsional strength of pin configurations used to fix supracondylar fracture of the humerus in children. *J Bone Jt Surg (Am)* 1994;76:253–256.